



# Metagenomic next-generation sequencing restores the diagnosis of a rare infectious complication of B cell depletion

Margaux Garzaro<sup>1,2</sup> · Lin-Pierre Zhao<sup>1</sup> · Nathalie De Castro<sup>3</sup> · Séverine Mercier-Delarue<sup>4</sup> · Francois Camelena<sup>4,5</sup> · Sabine Pereyre<sup>6</sup> · Marie Gardette<sup>6</sup> · Béatrice Berçot<sup>4,5</sup> · Marion Malphettes<sup>1</sup> · Cécile Bébear<sup>6</sup> · Jean-David Bouaziz<sup>2,7</sup> · Jérôme Le Goff<sup>4,8</sup> · Lionel Galicier<sup>1</sup> · Maud Salmona<sup>4,8,9</sup>

Received: 24 November 2021 / Accepted: 12 August 2022 / Published online: 24 August 2022  
© The Author(s), under exclusive licence to Springer-Verlag GmbH Germany, part of Springer Nature 2022

## Abstract

A 45-year-old female patient receiving rituximab for B cell non-Hodgkin follicular lymphoma presented unexplained recurrent fever, abdominal discomfort, and pollakiuria. We performed shotgun metagenomic sequencing from peri-kidney collection that identified a co-infection with *Mycoplasma hominis* and *Ureaplasma urealyticum*. The patient recovered with sequelae after appropriate antibiotic treatment was given.

**Keywords** B cell aplasia · Metagenomic next-generation sequencing · *Mycoplasma hominis*

## Introduction

Therapeutic B cell depletion can occasionally lead to long-lasting immune deficiency with rare infections. Progressive multifocal leukoencephalopathy was the first opportunistic infection described after rituximab [1]. Since then, various opportunistic infections including enteroviral meningoencephalitis and disseminated mycoplasma infections [2, 3] have been reported in the context of B cell depletion. These infections are typically encountered in patients suffering from primary immune deficiency such as X-linked agammaglobulinemia (XLA) and are difficult to diagnose with conventional microbiological tools. Metagenomics

analysis with next-generation sequencing enables to search unexpected microorganisms [4]. Here, we report a case of a patient with extragenital *Mycoplasma hominis* and *Ureaplasma urealyticum* infection consecutive to a secondary B cell aplasia, diagnosed with metagenomics analysis.

## Patient

A 45-year-old female patient was diagnosed and treated for a grade II B cell non-Hodgkin follicular lymphoma in January 2018 with 6 cycles of chemotherapy combining cyclophosphamide, doxorubicin, vincristine, and

✉ Margaux Garzaro  
margaux.garzaro@aphp.fr; margaux.garzaro@orange.fr

✉ Maud Salmona  
maud.salmona@aphp.fr

<sup>1</sup> Department of Clinical Immunopathology, Hôpital Saint-Louis, Assistance Publique Hôpitaux de Paris, 1, Avenue Claude Vellefaux, 75010 Paris, France

<sup>2</sup> Université de Paris, Paris, France

<sup>3</sup> Department of Infectious Diseases, Hôpital Saint-Louis, Assistance Publique Hôpitaux de Paris, Paris, France

<sup>4</sup> Department of Microbiology, Hôpital Saint-Louis, Assistance Publique Hôpitaux de Paris, Paris, France

<sup>5</sup> Bacteriology Department, Associated Laboratory of the French National Center for Bacterial Sexually Transmitted Infections, University of Paris, IAME, INSERM 1137, Paris, France

<sup>6</sup> Bacteriology Department, French National Center for Bacterial Sexually Transmitted Infections, CHU Bordeaux, and USC, University Bordeaux, 3671 Bordeaux, EA, France

<sup>7</sup> Department of Dermatology, Hôpital Saint-Louis, Assistance Publique Hôpitaux de Paris, Paris, France

<sup>8</sup> Team Insight, Université de Paris, INSERM U976, Paris, France

<sup>9</sup> Department of Virology, Hôpital Saint-Louis, 1 Avenue Claude Vellefaux, 75010 Paris, France

prednisone (CHOP) with the monoclonal anti-CD20 antibody rituximab. Thereafter, she underwent a maintenance therapy with rituximab every 2 months.

In May 2019, while rituximab injections were still ongoing, she complained about recurrent fever, abdominal discomfort, pollakiuria, and vaginal ulcers. Cytobacteriologic examination of the urine showed microscopic hematuria and leukocyturia with altered neutrophils but failed to identify any pathogens. C-reactive protein level was 64 mg/L. Neutrophils count was within the normal range and lymphocytes count was 600 lymphocytes/mm<sup>3</sup>. Peripheral blood lymphocyte phenotyping revealed B cell aplasia. Moreover, serum electrophoresis and nephelometry assessment of immunoglobulin levels showed severe hypogammaglobulinemia with 2.78 g/L, 0.29 g/L, and 0.14 g/L levels for IgG, IgA, and IgM, respectively. Computed tomography (CT) of the abdomen demonstrated disseminated thickening of bladder wall and right ureter consistent with urinary tract inflammation, as well as dilated right ureter and renal abscesses, leading to the placement of a double J ureteric stent. Urethrocytoscopic evaluation showed highly inflamed bladder wall. Biopsy revealed intense inflammation with granuloma and neutrophilic infiltration, without sign of tumoral or lymphocytic lesion. 16S ribosomal RNA sequencing on biopsy did not identify any bacterial component, and conventional bacterial culture remained negative. Several lines of antibiotics including cefotaxime, piperacillin-tazobactam, and imipenem failed to improve the patient's condition. Therefore, main hypotheses were Sweet syndrome with visceral involvement or aseptic abscesses syndrome. Rituximab was discontinued and corticosteroids were started, leading to rapid improvement of fever and pain, but persistence of systemic inflammation, with clinical relapses at any attempt of steroid tapering. Interleukin-1 receptor antagonist and colchicine failed as corticosteroids-sparing therapies. Anti-TNF $\alpha$  (infliximab) was started on February 2020.

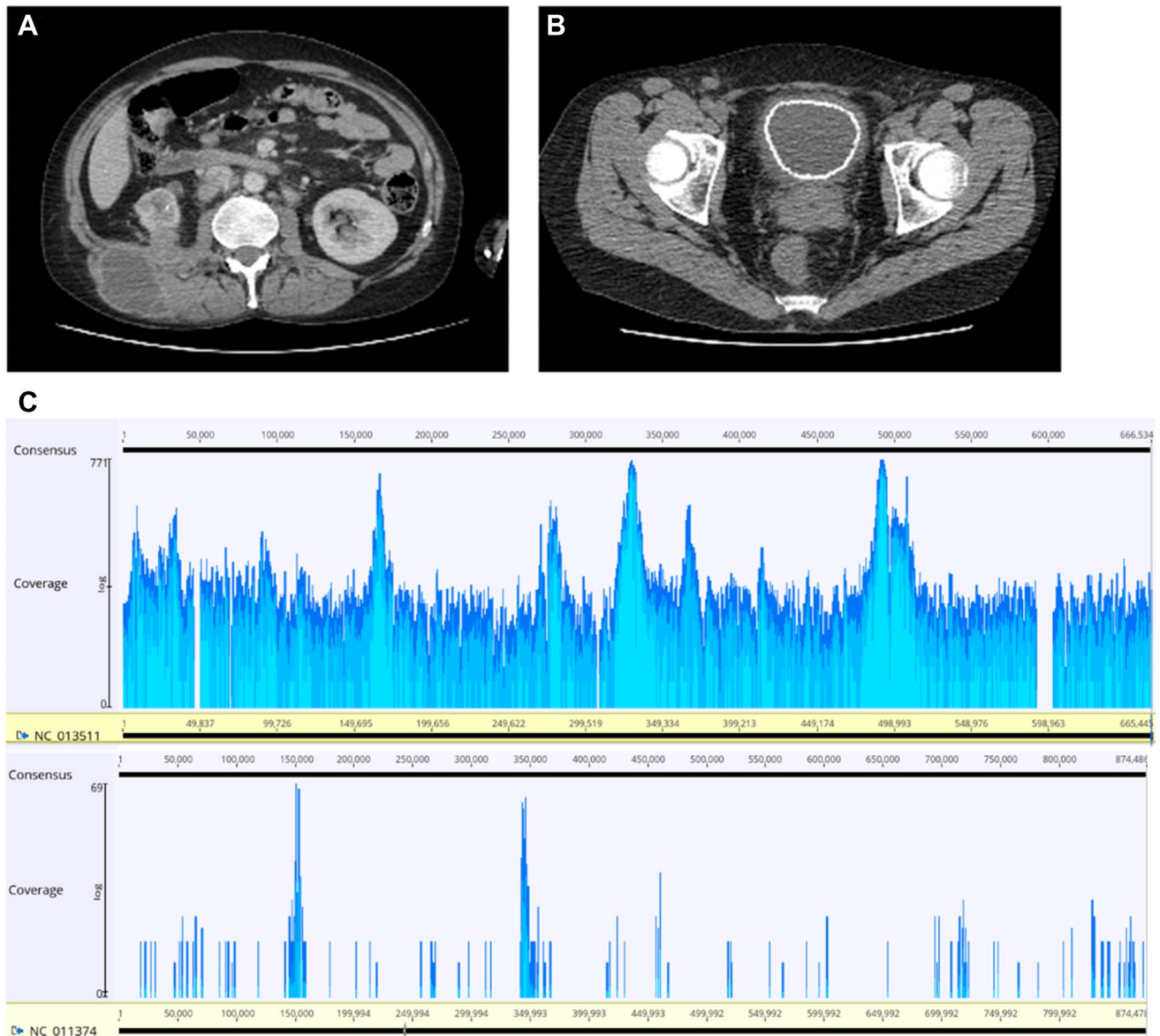
After two infliximab injections, she complained about fever and worsening pain. CT scan revealed a large collection located in the posterior side of the right kidney with perirenal infiltration (Fig. 1A), associated with whole bladder wall calcification (Fig. 1B). CT-guided paracentesis of the collection drained off purulent fluid. Bacterial and fungal cultures provided negative results. Metagenomic next-generation sequencing (mNGS) from collection was then performed and identified *M. hominis* and *U. urealyticum*. Torque Teno virus was also detected. Among 25.6 millions total sequencing reads, 121,596 belonged to *M. hominis* enabling an excellent genome coverage (92%, Fig. 1C) and 972 reads belonged to *U. urealyticum*. These two results were confirmed by a specific PCR

[5], in both fluid aspiration of the collection and the patient's urines. Despite the use of specific culture media, both *M. hominis* and *U. urealyticum* failed to grow in culture preventing the achievement of an antibiogram. Near complete genomes of *M. hominis* was recovered by mNGS allowing antibiotic susceptibility prediction. No acquired antibiotic resistance was reported. Due to the low coverage of *U. urealyticum*, antibiotic susceptibility prediction was not possible. Treatment with moxifloxacin and doxycycline started in April 2020 and drainage of the abscess rapidly led to apyrexia. Polyvalent immunoglobulin substitution was started. Presence of *M. hominis* and *U. urealyticum* in urines was monthly monitored with specific PCR. *U. urealyticum* was no longer detected after the first month of treatment. *M. hominis* was cleared since the third month of treatment. Treatment was stopped after 3 months with sustained bacterial clearance. Although abdominal CT evaluation confirmed abscess healing, urinary urgency and pollakiuria remain as sequelae of the bladder calcification requiring insertion of an indwelling urinary catheter.

## Discussion

*M. hominis* and *U. urealyticum* are opportunistic pathogens which belong to the class of mollicutes commonly referred to as mycoplasmas, and are part of the normal flora of the genitourinary tract. While infections due to these microorganisms have been reported secondary to genitourinary tract disruption (post-partum or perioperative setting) [6], most cases of disseminated infections occur in immunocompromised patients [2, 3].

Our case raises the question of the exact nature of the underlying immunosuppression favoring disseminated mycoplasmal infections. The link between humoral immunity and mycoplasmal infection is not clear. Previous reports suggested hypogammaglobulinemia to be the main predisposing factor [3]. This hypothesis is further supported by various observations: (i) hypogammaglobulinemia has been found to be frequently associated with disseminated mycoplasmal infections [2]; (ii) infections induce a raise of mycoplasmal-specific immunoglobulins which have been shown to be crucial in the clearance of some species of *Mycoplasma* in a mouse model [7]; and (iii) increased mucosal colonization is observed in patients with hypogammaglobulinemia [8], which could increase the risk of dissemination. However, these infections remain a rare complication among patients with primary or secondary hypogammaglobulinemia, suggesting that loss of immunoglobulins itself is not enough to predispose to mycoplasmal infections. Of note, 15 cases



**Fig. 1** Pretreatment CT scan. CT scan showing a large collection in the posterior side of the right kidney (A) and bladder calcifications (B). C Genomic coverage of *Mycoplasma hominis* and *Ureaplasma urealyticum*

of mycoplasmal or ureaplasma infections in the context of B cell aplasia (due to XLA ( $n = 4$ ), CVID ( $n = 7$ ), and post-rituximab deficiency ( $n = 4$ )) are described in the literature [9–20]. All cases were mono or polyarthritides, except for two cases of *M. hominis* chronic cystitis [9], one case of disseminated abscesses [16] and one case of meningitis [17]. *Ureaplasma spp* was reported in 8 infections including 7 *U. urealyticum* whereas *Mycoplasma spp* was involved in 7 infections including five *M. hominis*. In two cases [9] and in an additional case of a chronic infection due to *Spiroplasma apis* [21] (a honeybee specie of Mollicutes) in a patient with XLA, these infections occurred despite polyvalent immunoglobulin

substitution with normal level of residual IgG, supporting the hypothesis that B cell aplasia alone is the major risk factor for disseminated infection.

There are 17 described cases of disseminated infection with *Mycoplasma spp* or *Ureaplasma spp* in primary or secondary hypogammaglobulinemia, without mention of the B cell count [2, 22–37]. Cases were due to *Ureaplasma spp* ( $n = 10$ , including 7 *U. urealyticum*) and *Mycoplasma spp* ( $n = 7$ , including three *Mycoplasma salivarium*, two *Mycoplasma orale*, one *M. hominis*, and one *Mycoplasma pneumoniae*). As in B aplastic patients, the majority of infections were osteo-articular infections ( $n = 12$ ) [22–30, 35, 37]. There were also three

disseminated abscesses [2, 32, 33], a renal abscess [36], a brain abscess [34], and an endocarditis [31]. Finally, only one case of disseminated infection with *Ureaplasma* infection in a hypogammaglobulinemic patient with a normal B cell count has been reported [38].

Diagnosis can be challenging as standard bacterial cultures are frequently unable to identify the pathogen, due to their fastidious nature even on enriched blood agar plates. Moreover, the serological tests that can be helpful in chronic *Mycoplasma* infections [39] are often negative in case of profound hypogammaglobulinemia. Negative bacterial workup may lead to non-infectious misdiagnosis and inappropriate immunosuppressive therapy as in our case. Clinical metagenomics (CMg) is an emerging diagnostic tool in infectious diseases allowing to identify unexpected microorganisms with no prior assumption [40]. In addition to diagnosis, CMg enables infer their susceptibility to antimicrobials by antibiotic resistance genes (ARG) analysis.

In our case, CMg provided a diagnosis where traditional methods failed, including 16S Sanger sequencing. The failure of 16S ribosomal RNA Sanger sequencing may be explained not only by the difference in sampling and timing compared to CMg diagnosis but also by the polymicrobial nature of the infection [41]. Thanks to a sufficient genomic coverage, the antibiotic sensitivity of *M. hominis* could be predicted, allowing the implementation of an adapted treatment. Although the place of CMg is not well established especially in plasma [42], given the after-effects of our patient, CMg in sterile fluids should be rapidly performed in immunocompromised patients with unexplained and persistent infectious signs.

## Conclusion

Secondary B cell aplasia may be complicated by specific and rare infections, such as disseminated mycoplasma infections, replicating in some extent the phenotype of primary immunodeficiencies with absence of mature B cells. Diagnosis of these rare infections is challenging. Our identification of a rare infectious complication of B cell depletion by clinical metagenomics highlights the utility of this approach and supports its development as a second-line diagnostic tool in these populations, to allow earlier diagnosis and avoid non-infectious misdiagnosis.

**Author contribution** All authors directly contributed to the patient management. The first draft of the manuscript was written by MG and L-PZ, and all authors commented on previous versions of the manuscript. All authors read and approved the final manuscript.

**Data availability** Not applicable.

**Code availability** Not applicable.

## Declarations

**Ethics approval** For this observational case, no ethical approval is required.

**Consent to participate** Informed consent of the patient for writing the case was obtained.

**Consent for publication** Informed consent of the patient for publication was obtained.

**Conflict of interest** The authors declare no competing interests.

## References

- Goldberg SL, Pecora AL, Alter RS et al (2002) Unusual viral infections (progressive multifocal leukoencephalopathy and cytomegalovirus disease) after high-dose chemotherapy with autologous blood stem cell rescue and peritransplantation rituximab. *Blood* 99(4):1486–8. <https://doi.org/10.1182/blood.v99.4.1486>
- Nulens E, Van Praet J, Selleslag D et al (2016) A disseminated *Mycoplasma hominis* infection in a patient with an underlying defect in humoral immunity. *Infection* 44(3):379–381. <https://doi.org/10.1007/s15010-015-0859-6>
- Meyer RD, Clough W (1993) Extragenital *Mycoplasma hominis* infections in adults: emphasis on immunosuppression. *Clin Infect Dis* 17(Suppl 1):S243–249. [https://doi.org/10.1093/clindis/17.supplement\\_1.s243](https://doi.org/10.1093/clindis/17.supplement_1.s243)
- Kolb M, Lazarevic V, Emonet S et al (2019) Next-generation sequencing for the diagnosis of challenging culture-negative endocarditis. *Front Med (Lausanne)* 6:203. <https://doi.org/10.3389/fmed.2019.00203>
- Bébéar C, Pereyre S (2018) *Mycoplasma* et *Ureaplasma* spp, REMIC 6<sup>ème</sup> edition. Société Française de Microbiologie, Paris, France
- Whitson WJ, Ball PA, Lollis SS, Balkman JD, Bauer DF (2014) Postoperative *Mycoplasma hominis* infections after neurosurgical intervention. *J Neurosurg Pediatr* 14(2):212–218. <https://doi.org/10.3171/2014.4.PEDS13547>
- Meyer Sauter PM, de Groot RCA, Estevão SC et al (2018) The role of B cells in carriage and clearance of *Mycoplasma pneumoniae* from the respiratory tract of mice. *J Infect Dis* 217(2):298–309. <https://doi.org/10.1093/infdis/jix559>
- Furr PM, Taylor-Robinson D, Webster AD (1994) Mycoplasmas and ureaplasmas in patients with hypogammaglobulinemia and their role in arthritis: microbiological observations over twenty years. *Ann Rheum Dis* 53(3):183–187. <https://doi.org/10.1136/ard.53.3.183>
- Webster AD, Taylor-Robinson D, Furr PM et al (1982) Chronic cystitis and urethritis associated with ureaplasma and mycoplasma infection in primary hypogammaglobulinemia. *Br J Urol* 54(3):287–291. <https://doi.org/10.1111/j.1464-410x.1982.tb06977.x>
- Forgacs P, Kundsinn RB, Margles SW et al (1993) A case of *Ureaplasma urealyticum* septic arthritis in a patient with hypogammaglobulinemia. *Clin Infect Dis* 16(2):293–294. <https://doi.org/10.1093/clind/16.2.293>
- Franz A, Webster AD, Furr PM et al (1997) Mycoplasma arthritis in patients with primary immunoglobulin deficiency: clinical features and outcomes of 18 patients. *Br J Rheumatol* 36(6):661–668. <https://doi.org/10.1093/rheumatology/36.6.661>
- Arber C, Buser A, Heim D et al (2007) Septic polyarthritis with *Ureaplasma urealyticum* in a patient with prolonged

- agammaglobulinemia and B-cell aplasia after allogeneic HSCT and rituximab pretreatment. *Bone Marrow Transplant* 40(6):597–598. <https://doi.org/10.1038/sj.bmt.1705766>
13. Sato H, Lino N, Ohashi R et al (2012) Hypogammaglobulinemic patient with polyarthritis mimicking rheumatoid arthritis finally diagnosed as septic arthritis caused by *Mycoplasma hominis*. *Intern Med* 51(4):425–429. <https://doi.org/10.2169/internalmedicine.51.6058>
  14. Noska A, Nasr R, Neville Williams D (2012) Closed trauma, *Mycoplasma hominis* osteomyelitis, and the elusive diagnosis of Good's syndrome. *BMJ Case Rep* 2012:bcr2012007056. <https://doi.org/10.1136/bcr-2012-007056>
  15. George MD, Cardenas AM, Birnbaum BK et al (2015) Ureaplasma septic arthritis in an immunocompromised patient with juvenile idiopathic arthritis. *J Clin Rheumatol* 21(4):221–224. <https://doi.org/10.1097/RHU.0000000000000248>
  16. Dominguez-Pinilla N, Allende LM, Rosain J et al (2018) Disseminated abscesses due to *Mycoplasma faucium* in a patient with activated PI3K $\delta$  syndrome type 2. *J Allergy Clin Immunol Pract* 6(5):1796–1798.e2. <https://doi.org/10.1016/j.jaip.2018.02.014>
  17. Zhang T, Li H, Hou S et al (2021) Case report of *Ureaplasma urealyticum* meningitis in a patient with thymoma and hypogammaglobulinemia. *BMC Infect Dis* 21(1):1142. <https://doi.org/10.1186/s12879-021-06831-z>
  18. Bradhurst P, El-Haddad C, Ng J et al (2021) *Ureaplasma urealyticum* septic oligoarthritis in a patient with severe secondary hypogammaglobulinaemia. *Med J Aust* 214(11):506–507.e1. <https://doi.org/10.5694/mja2.51107>
  19. Bozo N, Ravn C, Justesen US et al (2021) *Mycoplasma hominis* septic arthritis in a patient with hypogammaglobulinaemia and rheumatoid arthritis. *BMJ Case Rep* 14(1):e237798. <https://doi.org/10.1136/bcr-2020-237798>
  20. Totten AH, Xiao L, Drabb DM et al (2021) Septic polyarthritis with *Mycoplasma salivarium* in a patient with common variable immunodeficiency: case report and review of the literature. *Access Microbiol* 3(4):000221. <https://doi.org/10.1099/acmi.0.000221>
  21. Etienne N, Bret L, Le Brun C et al (2018) Disseminated *Spiroplasma apis* infection in patient with agammaglobulinemia, France. *Emerging Infect Dis* 24(12):2382–2386. <https://doi.org/10.3201/eid2412.180567>
  22. Stuckey M, Quinn PA, Gelfand EW (1978) Identification of *Ureaplasma urealyticum* (T-strain Mycoplasma) in patients with polyarthritis. *Lancet* 2(8096):917–920. [https://doi.org/10.1016/s0140-6736\(78\)91632-x](https://doi.org/10.1016/s0140-6736(78)91632-x)
  23. So AK, Furr PM, Taylor-Robinson D et al (1983) Arthritis caused by *Mycoplasma salivarium* in hypogammaglobulinaemia. *Br Med J (Clin Res Ed)* 286(6367):762–763. <https://doi.org/10.1136/bmj.286.6367.762>
  24. Johnston CL, Webster AD, Taylor-Robinson D et al (1983) Primary late-onset hypogammaglobulinaemia associated with inflammatory polyarthritis and septic arthritis due to *Mycoplasma pneumoniae*. *Ann Rheum Dis* 42(1):108–110. <https://doi.org/10.1136/ard.42.1.108>
  25. Jorup-Rönström C, Ahl T, Hammarström L et al (1989) Septic osteomyelitis and polyarthritis with ureaplasma in hypogammaglobulinemia. *Infection* 17(5):301–303. <https://doi.org/10.1007/BF01650712>
  26. Mohiuddin AA, Corren J, Harbeck RJ et al (1991) *Ureaplasma urealyticum* chronic osteomyelitis in a patient with hypogammaglobulinemia. *J Allergy Clin Immunol* 87(1 Pt 1):104–107. [https://doi.org/10.1016/0091-6749\(91\)90219-e](https://doi.org/10.1016/0091-6749(91)90219-e)
  27. Lee AH, Ramanujam T, Edelstein PH et al (1992) Molecular diagnosis of *Ureaplasma urealyticum* septic arthritis in a patient with hypogammaglobulinemia. *Arthritis Rheum* 35(4):443–448. <https://doi.org/10.1002/art.1780350414>
  28. Steuer A, Franz A, Furr PM et al (1996) Common variable immunodeficiency presenting as a *Mycoplasma hominis* septic arthritis. *J Infect* 33(3):235–237. [https://doi.org/10.1016/s0163-4453\(96\)92441-x](https://doi.org/10.1016/s0163-4453(96)92441-x)
  29. Lehmer RR, Andrews BS, Robertson JA et al (1991) Clinical and biological characteristics of *Ureaplasma urealyticum* induced polyarthritis in a patient with common variable hypogammaglobulinemia. *Ann Rheum Dis* 50(8):574–576. <https://doi.org/10.1136/ard.50.8.574>
  30. La Scola B, Michel G, Raoult D (1997) Use of amplification and sequencing of the 16S rRNA gene to diagnose *Mycoplasma pneumoniae* osteomyelitis in a patient with hypogammaglobulinemia. *Clin Infect Dis* 24(6):1161–1163. <https://doi.org/10.1086/513631>
  31. Frangogiannis NG, Cate TR (1998) Endocarditis and Ureaplasma urealyticum osteomyelitis in a hypogammaglobulinemic patient. A case report and review of the literature. *J Infect* 37(2):181–184. [https://doi.org/10.1016/s0163-4453\(98\)80174-6](https://doi.org/10.1016/s0163-4453(98)80174-6)
  32. Paessler M, Levinson A, Patel JB et al (2002) Disseminated *Mycoplasma orale* infection in a patient with common variable immunodeficiency syndrome. *Diagn Microbiol Infect Dis* 44(2):201–204. [https://doi.org/10.1016/s0732-8893\(02\)00429-7](https://doi.org/10.1016/s0732-8893(02)00429-7)
  33. Cordtz J, Jensen JS (2006) Disseminated *Ureaplasma urealyticum* infection in a hypo-gammaglobulinaemic renal transplant patient. *Scand J Infect Dis* 38(11–12):1114–1117. <https://doi.org/10.1080/00365540600675734>
  34. Deetjen P, Maurer C, Rank A et al (2014) Brain abscess caused by *Ureaplasma urealyticum* in an adult patient. *J Clin Microbiol* 52(2):695–698. <https://doi.org/10.1128/JCM.02990-13>
  35. Thoendel M, Jeraldo P, Greenwood-Quaintance KE et al (2017) A novel prosthetic joint infection pathogen, *Mycoplasma salivarium*, identified by metagenomic shotgun sequencing. *Clin Infect Dis* 65(2):332–335. <https://doi.org/10.1093/cid/cix296>
  36. Jhaveri VV, Lasalvia MT (2019) Invasive *Ureaplasma* infection in patients receiving rituximab and other humoral immunodeficiencies—a case report and review of the literature. *Open Forum Infect Dis* 6(10):ofz399. <https://doi.org/10.1093/ofid/ofz399>
  37. Ketchersid J, Scott J, Lew T (2020) Recurrent multifocal *Mycoplasma orale* infection in an immunocompromised patient: a case report and review. *Case Rep Infect Dis* 9(2020):8852115. <https://doi.org/10.1155/2020/8852115>
  38. Vogler LB, Waites KB, Wright PF et al (1985) *Ureaplasma urealyticum* polyarthritis in agammaglobulinemia. *Pediatr Infect Dis* 4(6):687–691. <https://doi.org/10.1097/00006454-19851000-00020>
  39. Lo SC, Wang RYH, Grandinetti T et al (2003) Mycoplasma hominis lipid-associated membrane proteins antigens for effective detection of M. hominis-specific antibodies in humans. *Clin Infect Dis* 36(10):1246–1253. <https://doi.org/10.1086/374851>
  40. Chiu CY, Miller SA (2019) Clinical metagenomics. *Nat Rev Genet* 20(6):341–355. <https://doi.org/10.1038/s41576-019-0113-7>
  41. Deurenberg RH, Bathoorn E, Chlebowicz MA et al (2017) Application of next generation sequencing in clinical microbiology and infection prevention. *J Biotechnol* 243:16–24. <https://doi.org/10.1016/j.jbiotec.2016.12.022>
  42. Hogan CA, Yang S, Garner OB et al (2021) Clinical impact of metagenomic next-generation sequencing of plasma cell-free DNA for the diagnosis of infectious diseases: a multicenter retrospective cohort study. *Clin Infect Dis* 72(2):239–245

**Publisher's note** Springer Nature remains neutral with regard to jurisdictional claims in published maps and institutional affiliations.